

Management of Chronic Granular Hypertrophic Pharyngitis (Vrunda) through Ayurveda: A Paediatric Case Report

RIYA RAJENDRA RATHOR¹, RENU BHARAT RATHI²

ABSTRACT

The inflammation of the oropharyngeal mucous membranes, known as pharyngitis, is typically caused by a bacterial or viral illness but can also be attributed to allergies, trauma, malignancy, reflux, or various toxins. One of the most prevalent causes of paediatric antibiotic prescriptions is acute pharyngitis, which accounts for 2-5% of paediatric ambulatory visits. The primary clinical features of the modified Centor Score and Fever PAIN scoring systems are largely used to diagnose the cause and severity of pharyngitis. In the present case, a 15-year-old female who had been experiencing symptoms of a foreign body sensation, chronic cough, intermittent fever, and difficulty swallowing for a year was diagnosed with chronic granular hypertrophic pharyngitis and was treated with an Ayurvedic treatment protocol. The Ayurvedic therapy used for this patient comprised oral medication, *Panchakarma* therapy, and *Pranayama*. Patient follow-up and treatment were conducted consistently on the 7th and 15th days, and dietary modifications were also advised. After following the treatment, the patient showed improvement in chronic symptoms, and *Kawala* therapy provided relief from the symptoms. This case study aims to demonstrate the effectiveness and importance of Ayurvedic treatment principles in treating chronic granular hypertrophic pharyngitis, or Vrunda, in a paediatric patient.

Keywords: Catarrhal pharyngitis, Kawala, Nasya, Panchakarma, Vrunda

CASE REPORT

A 15-year-old female child, who was healthy one year ago, gradually developed complaints of throat pain accompanied by a foreign body sensation, a persistent cough, intermittent fever, difficulty swallowing, and halitosis. The patient has been suffering from all of these symptoms intermittently for one year. She visited a local hospital, where she was diagnosed with chronic granular hypertrophic pharyngitis and received conventional (modern) treatment for a month, during which she was prescribed antibiotics. However, she did not experience complete relief, as her symptoms would recur within a few days.

The patient further complained of an increase in pricking pain in her throat, especially in the early morning and at night, for the last five consecutive days. Consequently, she opted for Ayurvedic treatment for complete recovery and consulted the Outpatient Department (OPD) of *Kaumarbhritya*. She had no other relevant family history. The perinatal and birth history indicate that the child was born healthy, at full term, and weighed a normal 2.750 kg. An uneventful early postnatal period is evidenced by the baby's immediate crying after birth, the absence of birth asphyxia or hypoxic-ischaemic encephalopathy, and no history of time spent in the neonatal

intensive care unit. All vaccinations were administered according to the government schedule.

The child is developing physically in a healthy manner, as evidenced by developmental milestones and both gross and fine motor skills that are appropriate for her age. The family history reveals a non-consanguineous marriage. The child's past medical records indicate that she had normal eating habits, urination, and sleep patterns, reporting one to two episodes of clean bowel movements daily. However, she has a history of recurring illnesses and episodes of upper respiratory tract infections over the past year. There was no mention of any specific behavioural tendencies. The patient has never undergone surgery, and there is no history of metabolic diseases such as hypertension, diabetes mellitus, tuberculosis, asthma, or thyroid disease.

From the general and local examination, as mentioned in [Table/Fig-1], it was observed that the patient had a good build. Furthermore, the local examination of the throat suggested that she had developed chronic hypertrophy of the follicular tissue, leading to the aforementioned symptoms and suggesting the provisional diagnosis of Follicular Pharyngitis (*Vrunda*).

S. No.	General examination	Asthavidh pariksha	Systemic examination
1.	Pulse rate: 95/min	1. Nadi (pulse rate)- 95/min	• Examination of cardiovascular system: S1 S2 normal, no murmur
2.	Respiratory rate: 24/min	2. Mala- Nirama (1-2 times/day)	• Examination of respiratory system: AEBE, mild crepitus heard on auscultation
3.	Temperature: 99.8°F	3. Mutra- Prakrut (5-6 times/day)	• Examination of gastrointestinal system:
4.	Weight: 60 kg	4. Jihva- Nirama, mildly pallor, not coated	1. Inspection- normal
5.	Height: 155 cm	5. Shabda- Spashtha	2. Palpation- no any organomegaly seen
6.	Body mass index: 25	6. Sparsha- Samsheetushna	3. Percussion- resonant sound
		7. Druka- Prakrut, mildly pallor, no icterus	4. Auscultation- bowel sound present
		8. Akrti- Madhyam	5. Per abdomen- soft and non-tender
			• Examination of central nervous system: - Conscious and well oriented - Muscle power-5/5 - Reflexes - normal - Sensory system - normal

Local examination of throat:		
S. No.	Parameters	Findings
1.	Pharynx	Congestion was seen in the posterior wall of the pharynx
		Erythematous and swollen pharynx
		Increased mucous secretion
2.	Tonsils	Mild Tonsillar hypertrophy seen
3.	Uvula	Uvula hypertrophy along with congestion seen
4.	Lymph nodes	Tender anterior cervical lymphadenopathy

[Table/Fig-1]: General and systemic examination, Ashtavidh Pariksha along with local examination.

The patient was further assessed based on the Modified Centor Criteria [1] and Fever PAIN Scoring System [2], as shown in [Table/Fig-2], which concluded that the patient's symptoms improved after following the prescribed Ayurvedic treatment regimen [3,4].

Criteria and scoring system	Domains	Pre-treatment	Post-treatment
Modified centor criteria	Absence of cough	0	0
	Pyrexia (Fever >38°C)	1	0
	Tender, swollen Anterior cervical lymph nodes	1	0
	Age (5-15 years)	1	1
	Tonsillar exudates	0	0
Fever pain scoring system	Pyrexia (Fever >38°C, >24 hour)	0	0
	Tender lymph nodes	1	0
	Tonsillar exudates	0	0
	Cough	1	0

[Table/Fig-2]: Shows the severity as per the Modified Centor Criteria, and Fever pain scoring system on pre-post treatment [3,4].

Nidana Panchaka (Aetiopathogenesis)

Ayurvedic disease aetiopathogenesis for the occurrence of any pathology in humans can be explained through five basic steps: *Nidana* (Cause), *Purva Rupa* (Prodromal Symptoms), *Rupa* (Symptoms), *Upashaya* (Relieving Factors), and *Samprapti* (Pathogenesis). In this disease-specific case, it can be understood from [Table/Fig-1] described below. *Samprapti* (Pathogenesis) specifically comprises certain factors that explain how their vitiation from normalcy leads to the onset of disease in an individual. These factors are referred to as *Samprapti Ghatak*, and they play an important role in the occurrence of the disease, which can be further understood from [Table/Fig-3].

- **Nidana (cause):** Repeated respiratory tract infections, allergy to seasonal changes and allergens, low immune response to allergens, a diet high in fast foods such as chips and biscuits, poor hygiene, inadequate eating habits, and Pittaj Aahar (Pittavardhak Aahar).
- **Purva rupa (prodromal symptom):** Soreness in the throat, dryness in the throat, and mild cough.
- **Rupa (symptom):** Intermittent fever, cough with congestion, occasional cold associated with post-nasal drip, increased mucous secretions, dysphagia, and lymphadenopathy.

Samprapti Ghataka	Findings
Dosha	Tridosha, Vata ++, Kapha ++, Pitta +
Dushya	Rasa
Srotas (channels)	Rasavaha, Pranavaha
Srotodushti prakara (physiological vitiation type)	Sanga (obstruction), Khavaigunya (condition of Srotas which is susceptible to pathological changes)
Udbhava sthana (Site of origin)	Gala Pradesh (throat)
Vyakta Stana (Organs and System affected)	Kantha (neck and throat), Mukha (mouth)
Sadhyasadyata (Prognosis)	Sadhya (Treatable)

[Table/Fig-3]: Samprapti Ghatak (Aetiopathogenesis).

- **Upashaya (relieving factor):** *Gargling, Nasya, Snehapana* followed by *Virechana*.
- **Samprapti (pathogenesis).**

A persistent infection of the lymphoid tissues, submucosal layers, and pharyngeal mucosa is known as chronic pharyngitis. Pathology classifies chronic pharyngitis into two categories: hypertrophic pharyngitis and simple catarrhal pharyngitis. Certain medical conditions, such as chronic tonsillitis, laryngitis, pharyngeal and laryngeal tumours, and cervical spondylosis, are often mistaken for these conditions. Several other differential diagnoses were also considered and ruled out to arrive at the final diagnosis.

Symptoms such as polymorphic rashes, splenomegaly, posterior cervical adenopathy, and upper lip oedema raise the possibility of Epstein-Barr Virus (EBV) infections, which were not observed in this patient. Scarletiform rashes, tonsillar exudates, palatal petechiae, and anterior cervical lymphadenopathy can be indicative of bacterial infections. Angular cheilitis and uncomfortable white curd-like plaques or smooth red spots inside the oropharynx are symptoms of fungal pharyngitis; however, these were not observed and were thus ruled out.

Based on the above aetiopathogenesis and progression of the disease in this present case, the diagnosis of chronic granular hypertrophic pharyngitis (Vrunda) was made.

The Ayurvedic treatment plan described in [Table/Fig-4] includes both internal and external therapies, such as *Haritaki Kwatha* for detoxification, *Khadiradi Vati* for oral health, and *Triphala Kwatha* for gargling. It incorporates *Anutaila Nasya* for nasal clearing, *Shitopaladi Churna*, and *Yashtimadhu Churna* for respiratory and oral care. The regimen concludes with *Sadya Sneha* (oleation) and *Virechana* (purgation) for systemic detoxification.

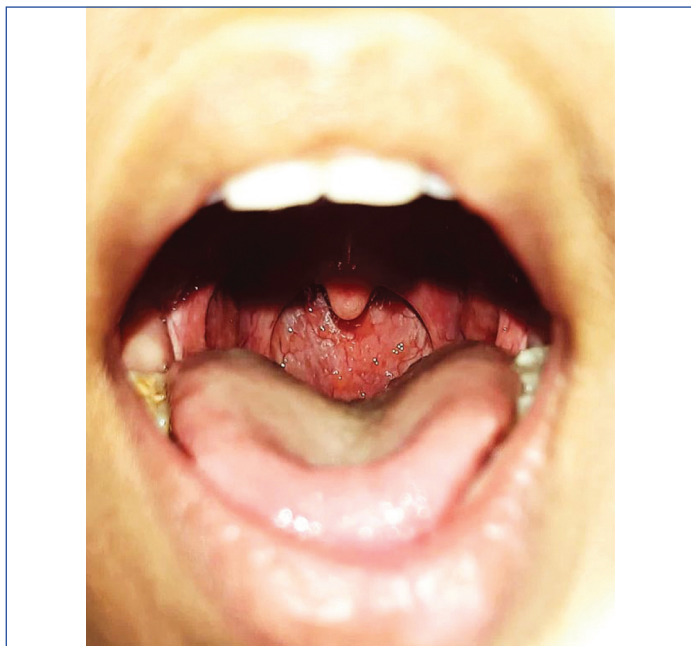
The patient was strongly advised against consuming chocolates, fast food, ice cream, cold beverages, and fermented foods. Dietary supplements, spicy meals, and any chemical or artificial colourings

S. No.	Medicine	Dose	Duration
1	<i>Haritaki Kwatha</i>	Twice a day with honey (5 mL before food)	For first 7 days
2	<i>Khadiradi vati</i>	(1 Tab - 4 times/day) <i>Chushanartha</i>	For 21 days
3	<i>Triphala kwatha+Darvi kwatha-Kawala</i>	Kawala (gargling) thrice a day	For 21 days
4	<i>Anutaila Nasya</i>	1-1 drop in each nostril	For last 7 days
5	<i>Shitopaladi Churna</i>	3 gm BD with Honey (Madhu)	Oral for 1 month
6	<i>Yashtimadhu Churna Pratisarana</i>	3 gm BD with Honey (Madhu) Local application and rubbing (<i>Pratisarana</i>)	For 15 days
7	<i>Sadya Sneha</i>	<i>Peya Sneha</i> (Bharjita Ghee)	for 5 days
8	<i>Virechana</i> (followed by 5 days of <i>Snehapana</i> and 1 day of rest period)	<i>Trivruta Lehya</i> - 10 gm	Stat- on day 7, after analysing <i>Samyak Sneha Siddhi Lakshana</i>

[Table/Fig-4]: Treatment plan.

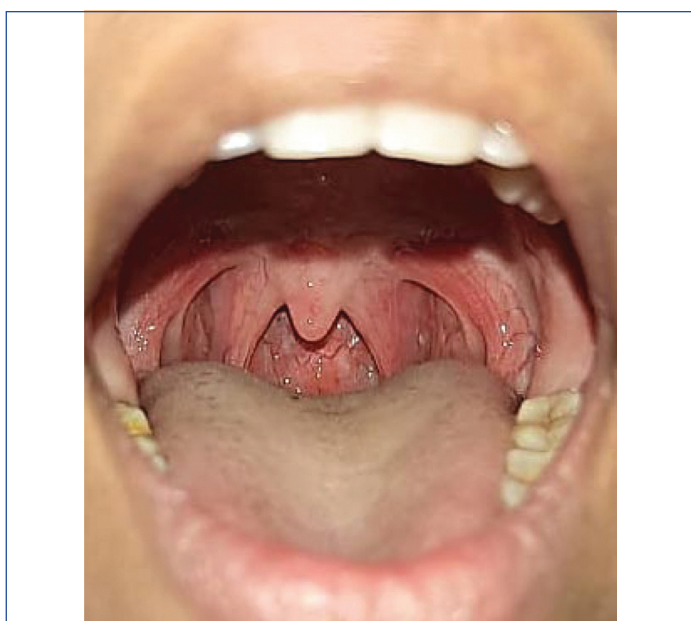
were to be avoided. The patient was instructed to clean her mouth regularly or wear a mask while in dusty and smoky environments. Additionally, she was advised to use a handkerchief in such situations and to inhale steam from the mouth using plain water, along with consuming heated food twice daily. Drinking lukewarm water throughout the day was also recommended.

The patient's clinical symptoms were recorded at intervals of every seven days. On day 0, the patient's posterior pharyngeal wall exhibited hypertrophy of follicular tissue, which had a granular glazed appearance [Table/Fig-5]. During the first follow-up after seven days, the patient reported a reduction in throat pain, fever, difficulty swallowing, and halitosis. By the seventh day, she completed the *Sadya Sneha* course and underwent *Virechana*. The patient experienced notable alleviation from pain and the foreign body sensation, following *Anutaila Nasya*, after the *Shodhana* process from *Virechana*, which was accompanied by hot water gargling.



[Table/Fig-5]: The patient's posterior pharyngeal wall showed hypertrophy of follicular tissue which had a granular glazed appearance (Day 0).

After 21 days, all medication was discontinued, and the patient was contacted for follow-ups every 15 days, subsequently shifting to once a month thereafter. No recurrence of symptoms was noted [Table/Fig-6].



[Table/Fig-6]: Post-treatment- The patient's pharynx in a state of healing and significant reduction in granular hypertrophy of tissues (day-14).

DISCUSSION

Chronic pharyngitis is a prolonged inflammatory condition of the pharynx, characterised by pathological enlargement of the mucosa, ceruminous glands, subepithelial lymphoid follicles, and the pharyngeal muscular sheath. Clinical evaluation, including physical examination and history-taking, is crucial for excluding serious conditions [5-7]. Symptoms include persistent tickling, dryness, soreness, pain during swallowing, and a sensation of a "lump of mucus" that prompts coughing. Pain often arises from the tubopharyngeal ridges and may involve hypertrophic and tender lymph nodes. Visible signs include inflammatory lymphoid granules and tonsillar hypertrophy [8-10].

The patient in this study presents with symptoms and signs consistent with chronic granular hypertrophic pharyngitis. The limitations of allopathic treatment for recurrent and chronic disorders in today's world draw attention to the Ayurvedic system of medicine. When viewing the condition based on clinical symptoms, *Vrunda* aligns more closely with pharyngitis after reviewing the traditional literature and detailed descriptions of *Kanthagatarogas*.

The Ayurvedic aetiopathogenesis of "*Vrunda*" begins with the influence of causative factors, reduced immunity, and unhealthy dietary and lifestyle habits (*Nidana Sevana*, *Alpa Vyadhikshamatva*, *Mithya Aharavihara*). This triggers an imbalance in the *Tridoshas*, primarily affecting *Kapha* and *Rakta*, with *Pitta* being secondarily involved. This imbalance impacts the *Rasavaha* and *Pranavaha Srotas* (circulatory and respiratory channels), leading to the development of throat irritation symptoms (*Kantha Gata Dushti Lakshan Utpatti*), which eventually culminate in "*Vrunda*."

Similarly, the pathogenesis of pharyngitis begins when a virus, bacterium, or irritant comes into contact with the pharyngeal mucosa, leading to an inflammatory response. In infectious cases, pathogens invade the mucosal tissue, prompting immune system activation and cytokine release, which cause localised inflammation, pain, redness, and swelling. This immune reaction leads to the common symptoms of pharyngitis, including throat pain and difficulty swallowing.

In managing this patient, the treatment principles of *Shodana*, *Shamana*, *Pathya Palana*, and *Kawala* were employed as part of the strategy for treating *Vrunda* [11-14].

To prevent the disease, *Charaka Acharya* recommends *Nidana Parivarjana*; therefore, the patient was advised to avoid consuming cold food, using air conditioning or other forms of artificial ventilation, and travelling without a helmet, among other precautions [15]. According to *Ayurveda*, *Mandagni* and each disease's unique causative components are considered the main causes of all diseases from a therapeutic perspective [16]. The *Virechana* medication *Trivrut Lehya* supports the maintenance of *Agni* in the body and is thus used to treat the *Anulomana* of *Vata* and *Malavishtambha*, as well as conditions related to *Kantharoga*, per *Ashtangahridaya* [17].

Sitopaladi Churna, being *Katu rasatmaka* and *Kapha shamaka*, decreases throat irritability and enhances throat soothing. *Yashtimadhu Churna* plays an important role as a *Swarya*, *Kanthy*, *Kandughna*, *Shonitasthapana*, and *Shothaghna*, due to its *Madhura Seeta Dravya gunas*. The anti-inflammatory, antipyretic, and anti-exudative properties of *Yashtimadhu Churna* are notable. To reduce excess mucosal secretion in the upper respiratory tract (Vitiated *Kapha*), *Yashtimadhu Churna*, *Sitopaladi Churna*, and honey are expected to be beneficial. For *Kawala*, it was decided to use *Triphala* and *Darvi Kwatha* (decoction) as *kawala* a straightforward treatment option with no side effects. *Triphala* is a popular herbal remedy, possessing medicinal properties such as *Raktashodhana*, *Ruksh guntmak*, *Kaphaghna*, *Rakta Sthambhan*, and *Raktashaman*. *Daruharidra* works as *Chedana*, *Vedanasthapana*, *Shothahara*, *Vranaropana*, *Deepana*, *Jwaraghna Karma*, *Raktashodhaka*, and *Varnya* in cases of *Mukharogas* and *Galagatarogas*.

In earlier case studies, particularly involving children, positive outcomes were achieved by combining Shamana aushadhi with Panchakarma procedures like Pratisarana and Kawal in adults [9,18]. However, in this case study, the patient's only means of alleviation were Virechana and a few Shamana aushadhis.

CONCLUSION(S)

Nidanaparivarjana rules played a crucial role in healing and avoiding recurrence. The treatment provided the patient with significant symptom alleviation, and no adverse drug reactions were observed. Patients with Vrunda may be treated with internal medication in addition to Virechana as Shodhana. A comprehensive clinical study involving a considerably larger patient group is necessary to statistically validate the effectiveness of this therapeutic procedure.

REFERENCES

- [1] McIsaac WJ, Kellner JD, Aufricht P. Empirical validation of guidelines for the management of pharyngitis in children and adults. *JAMA*. 2004;291(13):1587-95. Erratum in: *JAMA*. 2005;294(21):2700.
- [2] Little P, Hobbs FR, Moore M, Mant D, Williamson I, McNulty C, et al. Primary care Streptococcal Management (PRISM) study: In vitro study, diagnostic cohorts and a pragmatic adaptive randomized controlled trial with nested qualitative study and cost-effectiveness study. *Health Technol Assess*. 2018;18(6):vii-xxv, 1-101. Erratum in: *Health Technol Assess*. 2018;18(6):103-04.
- [3] Wolford RW, Goyal A, Belgam Syed SY. Pharyngitis. In: *StatPearls* [Internet]. Treasure Island (FL): StatPearls Publishing; 2023 Jan-. [Updated 2023 May 1; cited YYYY Mon DD]. Available from: <https://www.ncbi.nlm.nih.gov/books/NBK519550/>.
- [4] Alzahrani MS, Maneno MK, Daftary MN, Wingate L, Ettienne EB. Factors associated with prescribing broad-spectrum antibiotics for children with upper respiratory tract infections in ambulatory care settings. *Clin Med Insights Pediatr*. 2018;12:1179556518784300.
- [5] Faden H, Callanan V, Pizzuto M, Nagy M, Wilby M, Lamson D. The ubiquity of asymptomatic respiratory viral infections in the tonsils and adenoids of children and their impact on airway obstruction. *Int J Pediatr Otorhinolaryngol*. 2016;90:128-32.
- [6] Vidya NV, Bineesh EP, Vaghela DB. Ayurveda treatment protocol in the management of Galagraha (pharyngitis) - A case study. *J Ayu Herb Med*. 2020;6(2):63-65.
- [7] Dunmire SK, Hogquist KA, Balfour HH. Infectious mononucleosis. *Curr Top Microbiol Immunol*. 2015;390(Pt 1):211-40.
- [8] Semenov FV, Gorbonosov IV, Meleshkevich VB. Changes in regional hemodynamics during sanitizing operations on the middle ear and its pharmacological correction. *Proceedings of the XV All-Russian Congress of Otorhinolaryngologists*. SPb. 1995;399-402. [In Russian].
- [9] Bisno AL, Gerber MA, Gwaltney JM, Kaplan EL, Schwartz RH. Practice guidelines for the diagnosis and management of group A streptococcal pharyngitis. *Clin Infect Dis*. 2002;35:113-25. Doi: 10.1086/340949.
- [10] Gerber MA. Diagnosis and treatment of pharyngitis in children. *Pediatr Clin North Am*. 2005;52(3):729-47, vi. Doi: 10.1016/j.pcl.2005.02.004. PMID: 15925660; PMCID: PMC7118881.
- [11] Ng GJ, Tan S, Vu AN, Del Mar CB, van Driel ML. Antibiotics for preventing recurrent sore throat *Cochrane Database Syst Rev*. 2015;7:CD008911 10.1002/14651858.CD008911.pub2. PMID: 26171901.
- [12] Bisno AL. Practice guidelines for the diagnosis and management of group A streptococcal pharyngitis. *Clin Infect Dis*. 2014;39(2):101-09.
- [13] Cherry JD, Harrison GJ. Feigin and Cherry's Textbook of Pediatric Infectious Diseases. 8th ed. Elsevier Health Sciences; 2018.
- [14] Del Mar CB. Antibiotics for sore throat. *Cochrane Database Syst Rev*. 2017;(7):CD000023.
- [15] Charaka Samhita by Agnivesha with Ayurveda deepika teeka of Chakrapanidatta. Varanasi. Chaukhamba Surabharati Prakashana; Reprint, 201; 107.
- [16] Chavda K, Chhatbar DK, Parmar T, Meena RR, Nigam A. A conceptual study on rogaha sarvepi mandagnau (Mandagni is the Root Cause of all Diseases). *Ayushdhara*. 2024;11(3):113-17. 10.47070/ayushdhara.v11i3.1545.
- [17] Acharya Vagbhata, Ashtanga hrudayam sarvanga sundar commentary of arunadatta, Ayurveda Rasayana commentary of Hemadri, Edt by Bhisagacharya Harisastri paradakara vaidya, Edition Reprint 2020, published by chouxhambha orientalia, Varanasi, chapter no.-2, shloka no.-9, page no.-742.
- [18] Nasit J, Mehta B, Vaghela B. A case report: Management of granular pharyngitis with Ayurveda. *Int J Ayurvedic Med*. 2020;11(4):776-79. Doi: 10.47552/ijam.v11i4.1690.

PARTICULARS OF CONTRIBUTORS:

1. Postgraduate Scholar, Department of Kaumarbhritya, Mahatma Gandhi Ayurved College and Hospital and Research Centre, Salod, Hirapur, Wardha, Maharashtra, India.
2. Professor and Head, Department of Kaumarbhritya, Mahatma Gandhi Ayurved College and Hospital and Research Centre, Salod, Hirapur, Wardha, Maharashtra, India.

NAME, ADDRESS, E-MAIL ID OF THE CORRESPONDING AUTHOR:

Riya Rajendra Rathor,
Postgraduate Scholar, Department of Kaumarbhritya, Mahatma Gandhi Ayurved College and Hospital and Research Centre, Salod, Hirapur, Wardha, Maharashtra, India.
E-mail: riyarathor1495@gmail.com

PLAGIARISM CHECKING METHODS: [Jain H et al.]

- Plagiarism X-checker: Jun 26, 2024
- Manual Googling: Nov 27, 2024
- iThenticate Software: Dec 05, 2024 (4%)

ETYMOLOGY: Author Origin

EMENDATIONS: 8

AUTHOR DECLARATION:

- Financial or Other Competing Interests: None
- Was informed consent obtained from the subjects involved in the study? Yes
- For any images presented appropriate consent has been obtained from the subjects. Yes

Date of Submission: Jun 21, 2024

Date of Peer Review: Sep 02, 2024

Date of Acceptance: Dec 07, 2024

Date of Publishing: Jun 01, 2025